

CLINICAL AND HISTOLOGIC CHANGES DETERMINE OPTIMAL TREATMENT REGIMENS FOR MICRODERMABRASION

Bruce M. Freedman, MD, Eugenia Rueda-Pedraza, MD, Robert V. Earley, BSN

Plastic Surgery Associates of Northern Virginia, McLean, VA and Department of Pathology, Reston Hospital Center, Reston, VA

INTRODUCTION

Microdermabrasion has become a cornerstone of non-ablative facial rejuvenation. It has been used to successfully treat dyschromia, fine wrinkles, acne and mild scarring in all skin types. Its appeal has stemmed from the rapid recovery and limited risks associated with the procedure.

The purpose of this study was to identify and correlate the clinical and histologic changes observed during and after a series of microdermabrasion treatments to determine optimal treatment timing and frequency.

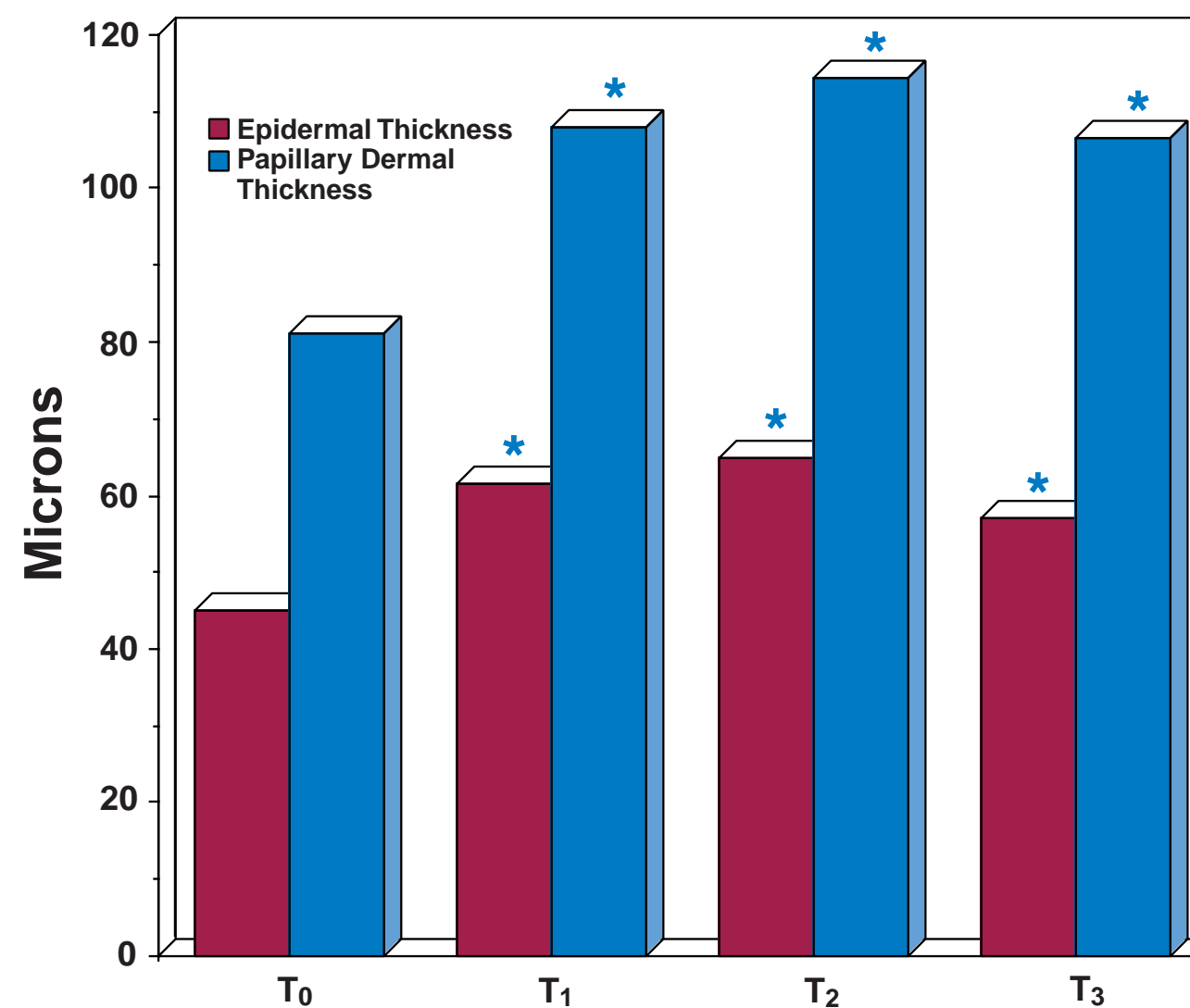
TREATMENT PROTOCOL

- ▶ Eleven Caucasian patients, ages 31-62
- ▶ Equipment – Power Peel® 2000 M unit (Aesthetic Lasers Inc. Annapolis, MD, USA)
- ▶ Treatment performed at 7-10 day intervals –
 - ◆ 5-7 passes of hand piece
 - ◆ Vacuum level at 40-50 mm Hg
 - ◆ Endpoint – erythema
- ▶ Photographs for documentation taken-
 - ◆ At beginning of study period (T0)
 - ◆ After third treatment (T1)
 - ◆ After sixth treatment (T2)
 - ◆ 90 days after sixth treatment (T3)
- ▶ Full thickness biopsies from the left (treated) and right (control) post-auricular areas
 - ◆ At beginning of study period (T0)
 - ◆ After third treatment (T1)
 - ◆ After sixth treatment (T2)
 - ◆ 90 days after sixth treatment (T3)
- ▶ Avoidance 6 weeks prior to and during the study period of the following items:
 - ◆ Antioxidants
 - ◆ Retinols
 - ◆ Topical acids

RESULTS

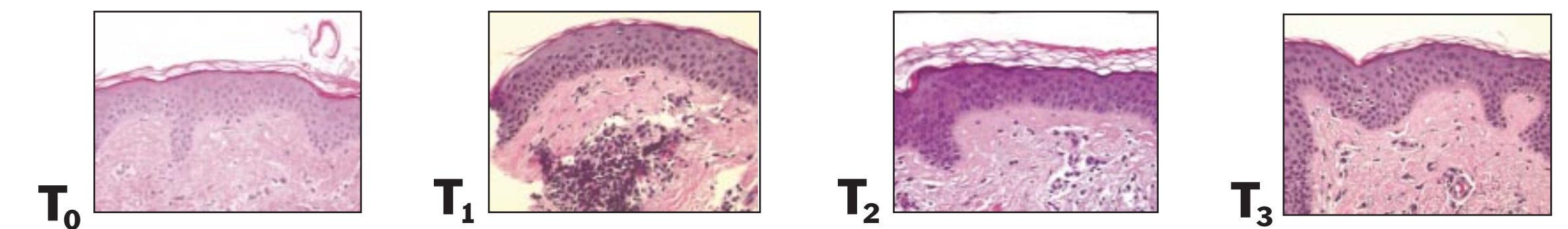
HISTOLOGIC RESULTS

*p<.01



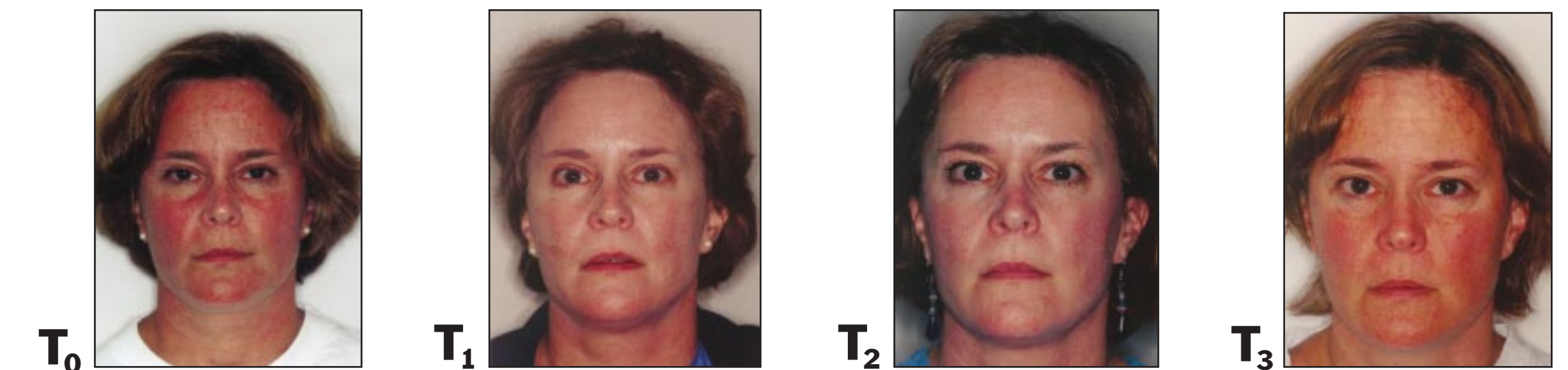HISTOLOGIC CHANGES

Hematoxylin and Eosin Stain (original magnification 20x)

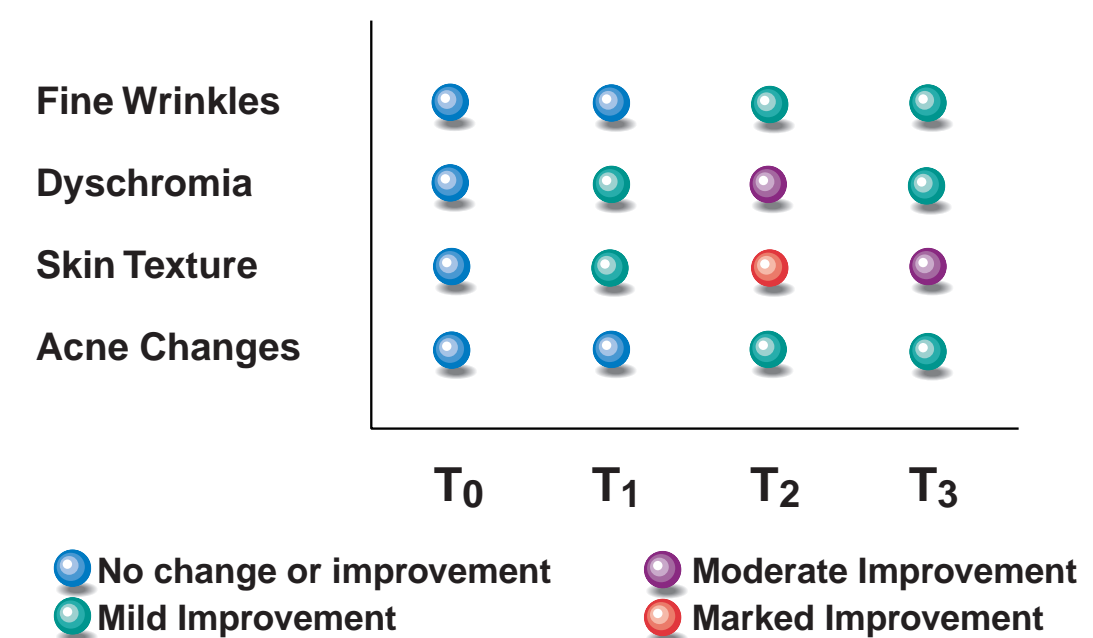


CLINICAL RESULTS

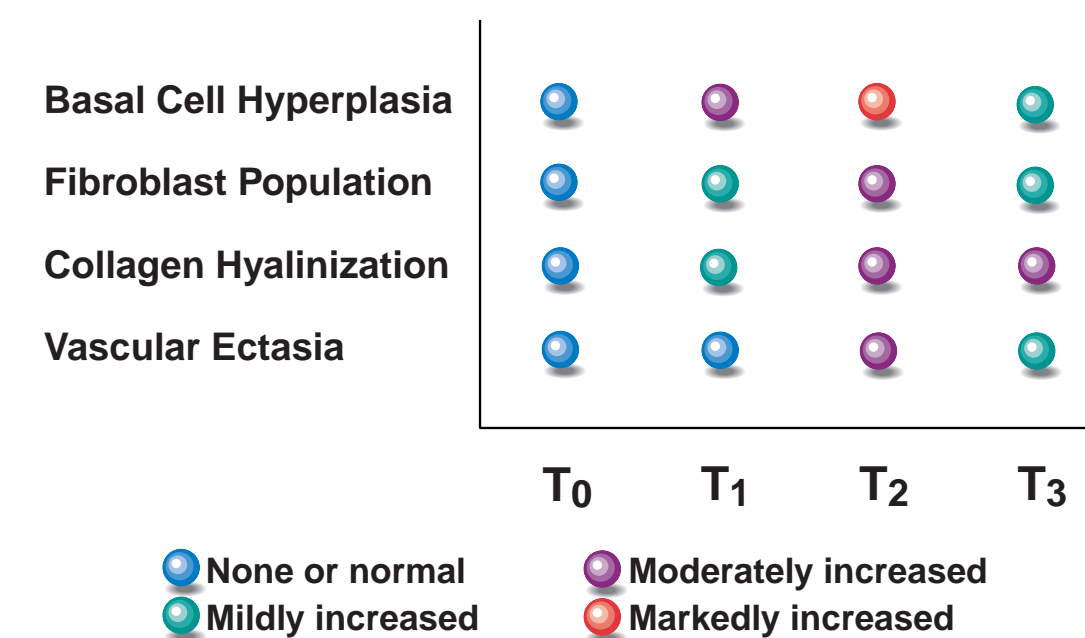
Patient photographs



CLINICAL OBSERVATIONS



HISTOLOGIC RESULTS



CONCLUSION

This study concludes that the clinical and histological changes are most likely secondary to a mechanism resembling a soft tissue reparative process at the dermal and epidermal levels. The persistent changes after a period of no treatment suggest that some of the changes could be permanent.

We propose that an initial series of 6 microdermabrasion treatments be employed to improve facial skin quality. A no-treatment period of 90-120 days can ensue, followed by 2-3 additional treatments to reenhance the clinical and histological condition. This cycle could be repeated to maintain a stable level of facial rejuvenation.